

[IJP] Submission Acknowledgement

From: Prof. Dr. Sugiyanto, SU., Apt. (mfi@ugm.ac.id)

To: lanhadi@yahoo.com

Date: Friday, May 31, 2019 at 07:51 AM GMT+7

Dr Lannie Hadisoewignyo:

Thank you for submitting the manuscript, "Hepatoprotective effects of Curcumin-Mesoporous Silica Nanoparticles on CCl 4 -induced Hepatotoxicity Wistar rats" to Indonesian Journal of Pharmacy. With the online journal management system that we are using, you will be able to track its progress through the editorial process by logging in to the journal web site:

Manuscript URL:

<http://indonesianjpharm.farmasi.ugm.ac.id/index.php/3/author/submission/1550>

Username: lhadisoewignyo

If you have any questions, please contact me. Thank you for considering this journal as a venue for your work.

Prof. Dr. Sugiyanto, SU., Apt.
Indonesian Journal of Pharmacy

INDONESIAN JOURNAL OF PHARMACY
Faculty of Pharmacy, Universitas Gadjah Mada
Skip Utara, 55281 Yogyakarta

Re: Revising Required

From: Ivonne Soeliono (ivonne.soeliono@gmail.com)

To: lanhadi@yahoo.com

Date: Friday, March 8, 2019 at 12:07 PM GMT+7

Dear Editor of IJP,

Herewith I send you our response to your suggestion.

1. The negative and positive control mentioned in our abstract referred to normal control and CCl₄ control. We have revised terms in the abstract.
2. In the methods section, we mentioned that the curcumin group was administered 2 mg/kg b.w. curcumin dan the C-MSN group was administered 10 mg/kg b.w. C-MSN. C-MSN contain 50 mg of curcumin and 200 mg of MSN (ratio 1:5). So that we adjusted the C-MSN dose to 10 mg/kg b.w. to maintain the equality of the curcumin dose between groups.
3. We already planned the MSN toxicity in our future study.
4. C-MSN has a lower ALT and AST level, and also a lower necrotic cells number than in CCl₄ control group. So that we concluded that the hepatoprotective effect of C-MSN is excellent and comparable to curcumin.

Thank you for your editorial suggestion.

We are waiting for your future consideration.

Sincere regards,

Lannie Hadisoewignyo

On Thu, Feb 28, 2019 at 1:12 PM lanhadi <lanhadi@yahoo.com> wrote:

Sent from my Samsung Galaxy smartphone.

----- Original message -----

From: Majalah Farmasi <mfi@ugm.ac.id>

Date: 2/28/19 13:06 (GMT+07:00)

To: Dr Lannie Hadisoewignyo <lanhadi@yahoo.com>

Subject: Revising Required

Dear Lannie Hadisoewignyo,

We have reached a decision regarding your submission to Indonesian Journal of Pharmacy, **"Hepatoprotective Effect of Curcumin-mesoporus Silica Nanoparticles on CCl₄-induced Hepatotoxicity**

Wistar Rats". Before we send your manuscript to our reviewer, please revise the editorial suggestion to improve your manuscript :

1. What do you mean with negative & postivie control?, They are normal group & untrecefeel, Hepatotoxicity abstract?
2. In methodology using the dose of curcumin between groups are different. (2 mg/kg b.w. vs 10 mg/kg b.w.)?
3. I think hepatoprotective trof of MSN should be included the test in order to have a complite conclusion this article still leave several question please complite the data.
4. Please provide data which explain whatever the C-MSN we have been made was successful

we hope your manuscript could be revise during 2 week.

sincerely
editor

1



Lannie_Hadisoewingnyo (format IJP-rev1).docx
6.5MB

(No Subject)

From: Majalah Farmasi (mfi@ugm.ac.id)

To: lanhadi@yahoo.com

Date: Friday, May 31, 2019 at 12:54 PM GMT+7

Dear Lannie Hadisoewigno

Your manuscript has been accepted for publication in Indonesian Journal of Pharmacy (attached 1). On behalf of Editorial team, we are looking forward to receiving your new paper. Please sign the copyright transfer (attached 2) in order to allow me to process your manuscript. Please check the proof (attached 3) carefully and if you need revision you can write in file (attached 4)

Regards
Editor in Chief,
Indonesian Journal of Pharmacy

Prof. Dr. Sugiyanto



2. Copyright from - MFI.docx
66.1kB



1. LOA LH.pdf
556.4kB



3. Galley Proof.pdf
871.1kB



4. Files.docx
8.6MB

Hepatoprotective effects of Curcumin-Mesoporous Silica Nanoparticles on CCl₄-induced Hepatotoxicity Wistar rats

Lannie Hadisoewignyo^{1*}, Ivonne Soeliono¹, Sandy Budi Hartono², Eka Pramhyrta Hestianah³, and Sri Rahayu Mahanani¹

1. Faculty of Pharmacy, Widya Mandala Catholic University Surabaya, Jalan Raya Kalisari Selatan No. 1, Pakuwon City, Surabaya, Indonesia, 60112
2. Faculty of Engineering, Widya Mandala Catholic University Surabaya, Jalan Kalijudan No. 37, Surabaya, Indonesia, 60114
3. Faculty of Veterinary Medicine, Airlangga University, Campus C, Mulyorejo, Surabaya, 60115

Info Article

Submitted: 26-01-2019

Revised: 27-05-2019

Accepted: 29-05-2019

*Corresponding author
Lannie Hadisoewignyo

Email:
lanhadi@yahoo.com

ABSTRACT

It has been reported that curcumin has a hepatoprotective effect, but its low solubility limited its utilization. Recently there was so many emerging research of advanced curcumin formulation, such as nanoparticles curcumin. In our previous study, curcumin has been loaded into mesoporous silica nanoparticles (C-MSN). This study was performed both to evaluate of C-MSN hepatoprotective effect in CCl₄ induced rats. Sixteen rats were divided into four groups, namely normal and CCl₄ control, curcumin, C-MSN group. Treatment was given according to its group for fourteen days consecutively. At day 14, three hours after the last administration, CCl₄ (1.25mL/kgBB) were administered orally. Twelve hours later the rats were sacrificed, and blood samples were drawn from their hearts. Blood serum examination result revealed that C-MSN caused a significantly lower ALT and AST than CCl₄ control group (851±271U/L vs 1734±275U/L; 295±155U/L vs 1348±235U/L; p<0.05). Its effect on hepatic serum level resembled curcumin group. However, the result was not supported by histology examination which showed a higher number of necrotic hepatic cells in C-MSN group than in the curcumin group (147±9 vs 80±16; p<0.05). From this study, it can be concluded that C-MSN revealed an excellent hepatoprotective property, but it was suspected that MSN itself has the toxic effect on the liver. A further study of MSN toxicity was needed to support its safety use.

Keywords: curcumin, curcumin nanoparticles, hepatoprotection, carbon tetrachloride.

INTRODUCTION

Curcuma longa L. (Zingiberaceae) or turmeric is used widely in Indonesia as food spices. However, turmeric has potential as a medicine, beauty aid, cooking spice, and as a dye (Omosa *et al.*, 2017). *C. longa* contains curcumin, a natural polyphenol, and a primary yellow pigment. Curcumin is one of the curcuminoids in the rhizome that has many activities such as hepatoprotective, antioxidant, antineoplastic, anti-bacterial, antiviral, antifungal, anti-inflammatory, antidiabetic, anticoagulant, antifertility, cardiovascular protective, and immunostimulant activity. Therefore, curcumin is believed as one of the

constituents responsible for bioactivities of the rhizome of this plant.

In several previous studies, *C. longa* was reported to have a hepatoprotective effect against CCl₄ hepatic damage induction (Girish and Pradhan, 2012; Hismiogullari *et al.*, 2014; Kim *et al.*, 2014; Lee *et al.*, 2017; Marslin *et al.*, 2018; Paolo and Kateri, 2017; Park *et al.*, 2000; Saygili *et al.*, 2016; Singh *et al.*, 2014; Wu *et al.*, 2008; Zhao *et al.*, 2014). Fermented *C. longa* is showing a hepatoprotective effect by suppressing oxidative stress caused by CCl₄ (Kim *et al.*, 2014). *C. longa* (30, 300mg/kg b.w.) given orally for 14 days has inhibited alanine aminotransferase (ALT),

aspartate aminotransferase (AST), alkaline phosphatase (ALP), and lactate dehydrogenase (LDH) (Kim *et al.*, 2014). It also enhanced antioxidant activities so that it was suitable as a candidate for various liver diseases prevention associated with oxidative stress (Kim *et al.*, 2014). Aqueous extract of *C. longa* also reported having amelioration property to CCl₄-induced hepatotoxicity in Swiss albino mice (Sengupta *et al.*, 2011). Its methanol extract also showed an ameliorating effect on galactosamine-induced liver injury in mice (Adaramoye *et al.*, 2010). Its ethanol soluble fraction also has been proven to have a hepatoprotective effect on tacrine-induced cytotoxicity in human liver-derived HepG2 cells (Song *et al.*, 2001). Curcumin hepatoprotective activities were also evidenced in lipopoly-saccharide/d-galactosamine model of liver injury in rats. It decreases ALT and AST levels as well as lipid peroxidation activities (Černý *et al.*, 2011).

In the clinical setting, the use of curcumin as hepatoprotection agent in the patient with liver cirrhosis has been a standard clinical treatment in an Indonesian hospital. Nowadays, the use of curcumin as one of the liver cirrhosis therapy is also an increasing trend (Farida *et al.*, 2013; Tandi, 2017; Virgonita and Karim, 2012). However, the effectiveness of curcumin as a drug is limited by its chemical properties. Curcumin has low bioavailability because it has negligible solubility in water and only limited solubility in ethanol or acetone. Some researchers prepare an innovative breakthrough by loading curcumin into nanoparticles. Some previous hepatoprotective study showed that curcumin nanoparticles also have hepatoprotection effect, even better than curcumin. Solid lipid nanoparticles loaded with curcumin (C-SLN; 12.5mg/kg b.w.) given daily for four weeks showing a significant effect as an antioxidant and as a protector of liver damage in CCl₄ subchronic induction. C-SLN has a 62.07 and 83.37% inhibition of hepatic impairment resulting in 2.63 and 6.01 fold alleviation in ALT and AST values, respectively (Singh *et al.*, 2014). Curcumin also has been loaded in nanoparticles prepared from PLGA and PVA was given four times a week with CCl₄ given two times a week. That curcumin nanoparticles showed a good hepatoprotection effect as AST, ALT, and ALP value was decreased, and no damage was found in liver tissue treated with nano-curcumin (Marslin *et al.*, 2018).

In our previous research curcumin has been loaded into mesoporous silica nanoparticles (C-MSN). It has been proven that C-MSN has a higher

bioavailability than 'free curcumin' (Hartono *et al.*, 2016) so that it was expected to have a better hepatoprotection activity. In the present study, the C-MSN hepatoprotective effect will be evaluated against curcumin. To best of our knowledge, this is the first report of cubical curcumin-amine functionalized mesoporous silica nanoparticles (C-MSN) hepatoprotection effect.

MATERIAL AND METHODS

Sample and chemicals

Curcuma longa L. dry extract was purchased from and certified by Java Plants (Solo, Indonesia). C-MSN was prepared according to the method described by Hartono *et al.* (2016). Materials for C-MSN hepatoprotective study are carbon tetrachloride (E-Merck, Germany), corn oil (PT. Jaya Utama Santika, Indonesia), formaldehyde (Sigma Aldrich, Singapore), monosodium and disodium phosphate and (PT. Labtech Citra Persada, Indonesia), alcohol 96% (Sigma Aldrich, Singapore), sodium carboxymethylcellulose 0.5% as vehicles (Sigma Aldrich, Singapore), sterile sodium chloride 0.9% (Otsuka, Indonesia), water for injection (Otsuka, Indonesia).

Animals

Eight until twelve-week-old male Wistar rats (*Rattus norvegicus*) with body weight (b.w.) of 109-127g were obtained from a veterinarian breeder. All animals transferred into the animal laboratory in Widya Mandala Catholic University, Surabaya, Indonesia to be acclimatized for seven days. Rats were housed under 12h light/dark cycle and fed with standard laboratory diet and water ad libitum. Ethical approval was requested from the Animal Ethics Committee at Gadjah Mada University, Yogyakarta, Indonesia (Certificate no: 00108/04/LPPT/XII/2018).

C-MSN preparation

MSN preparation was done using a method published in our previous paper. 0.5g of triblock poly(ethylene oxide)-b-poly(propylene oxide)-b-poly(ethylene oxide) copolymer EO₁₀₆PO₇₀EO₁₀₆ (Pluronic® F127, MW=12600) and 1.4 of fluorocarbon surfactant (FC-4) mixed in the solutions of 60mL of 0.02M HCl then 0.5g of 1,3,5-trimethylbenzene (TMB) was added. Tetraethoxysilane (TEOS, 99%) was added after four h stirring and continued for 24h at 20°C. The substance was heated at 130°C for 24h in an autoclave then it was separated, washed and dried. Its surfactant was removed by calcination at 550°C

for six h. Amine functionalization was performed by grafting method where 0.6g of mesoporous silica (MSN) was added into 30mL toluene. It was stirred and heated to 70°C, and 1.2mL of 3-aminopropyltriethoxysilane (APTES, 99%) was added into the mixture, then the stirring was continued for 20h. The substance then centrifuged and dried. After the MSN was ready, curcumin was loaded into MSN. 50mg of curcumin and 200mg of MSN was mixed within a rotary evaporation flask. After added 20mL of ethanol, the mixture was sonicated for 2min with a Bath sonicator. Ethanol was evaporated slowly under vacuum at a temperature of 55°C. Finally, curcumin loaded MSN was obtained (Hartono *et al.*, 2016).

Experimental groups determination

The method used in this study refers to the hepatoprotective testing method from Kim *et al.* (2014). There were four animal groups in this experiment. Each group was consists of four animals. The animal was grouped randomly with regards to minimalized body weight variation within the group. All substances were administered by gastric intubation. The administration was done continuously for 14 days daily. The curcumin group was administered 2mg/kg b.w. Curcumin. The C-MSN group was administered 10mg/kg b.w. C-MSN. Curcumin and C-MSN powder were prepared in mucilage form with 0.5% CMC-Na. The normal and CCl₄ control group rats were administered only 0.5% CMC-Na. At day 14, three hours after last administration, curcumin, C-MSN, and CCl₄ control group were administrated CCl₄ 1.25mL/kg b.w, dissolved in 20% corn oil. CCl₄ was administered using gastric intubation method. The control group rats were only given 20% corn oil. Rats were anesthetized 12h after CCl₄ treatment under ketamine 40mg/kg b.w. and xylazine 7mg/kg b.w. (intraperitoneally) to collect the blood sample. After the blood sample was taken from the heart, cervical dislocation and abdominal incision were performed to collect liver from the rats.

Hepatic enzymes analysis

Blood samples collected from rats were centrifuged to separate sera. Sera were prepared for analysis according to the manual procedure of biochemical autoanalyzer (Prestige 24i Tokyo-Boeki, Japan). International Federation of Clinical Chemistry (IFCC) method was performed to determine aspartate aminotransferase (AST),

alanine aminotransferase (ALT) and alkaline phosphatase (ALP) level.

Histology examination of the liver

All portions of the liver were fixed in 10% buffered formalin solution for 24h and then trimmed. The liver tissue (n=4/ group) were gradually dehydrated in 70% alcohol, 80% alcohol, 90% alcohol, 96% alcohol, xylol, and liquid paraffin. Next step is tissue vacuuming and embedding. Liver tissue was sectioned at a thickness of 4-6µm and then processed with hematoxylin and eosin staining. Tissue was observed under a microscope (Olympus CX-21, Japan with Optilab® Advanced Plus, Indonesia) with 400 times magnification. Five hundred cells were counted for each preparation slide, and those cells were classified into normal, degenerated, and necrotic cells (Amdalia *et al.*, 2017).

The H&E stained sections were evaluated under light microscopy. Five hundred cells were counted in five visual fields (from the upper left of the to the right direction of preparation). Those cells were then classified into normal, degenerated, and necrotic cells (including karyopyknotic, karyorrhexis, and karyolysis cells) (Amdalia *et al.*, 2017; Nayak *et al.*, 2016).

Statistical analysis

ALT, AST, ALP, number of necrotic and degenerated liver cells are presented as mean ± SD of 4 replicates. All data were statistically analyzed using IBM SPSS Statistics for Windows, Version 24.0 (IBM Corp., USA). After testing the normality of the data distribution using a Shapiro-Wilk test, one-way analysis of variance (ANOVA) was performed. LSD multiple comparisons were performed as a post-hoc test to see any significant differences between each group. A 0.05 level was adopted for any significant difference.

RESULT AND DISCUSSION

Carbon tetrachloride (CCl₄) induced a very significant increase in ALT, AST, ALP (p<0.05), namely 29, 9, and two times of normal control group value, due to severe damage of the liver cells (Table I). This result is in line with the previous study result that supports CCl₄ as a preferred chemical compound to induce animal hepatic cell damage. (Girish and Pradhan, 2012; Hismiogullari *et al.*, 2014; Y. Kim *et al.*, 2014; Lee *et al.*, 2017; Marslin *et al.*, 2018; Paolo and Kateri, 2017; Park *et al.*, 2000; Saygili *et al.*, 2016; Singh *et al.*, 2014;

Table I. Effect of curcumin and C-MSN on hepatic serum markers of CCl₄-induced rats.

Group	ALT (U/L)	AST (U/L)	ALP (U/L)
Normal control	59±2 ^c	153±21 ^b	435±78 ^b
CCl ₄ control	1734±275 ^a	1348±235 ^a	754±74 ^a
Curcumin	879±272 ^b	656±358 ^{ab}	724±116 ^a
C-MSN	851±271 ^b	295±155 ^b	819±58 ^a

Data express the mean ± S.E.M for four rats (in units/liter). AST, aspartate aminotransferase; ALT, alanine aminotransferase; ALP, alkaline phosphatase. Means sharing a different subscript in a column are significantly different (LSD multiple comparison test, $p < 0.05$).

Wu *et al.*, 2008; Zhao *et al.*, 2014). Hepatic damage induction using CCl₄ it is easily reproducible, and it simulates human liver cirrhosis quite well by the generation of oxidative stress and induces proinflammatory and profibrotic cytokines. CCl₄ is converted into CCl₃· in the liver. Its exposure to O₂ result in CCl₃· transformation to CCl₃O₂·. CCl₃· and CCl₃O₂· are highly reactive to bind to lipid and protein. Those radicals could remove a hydrogen atom from unsaturated lipids and causes lipid peroxidation. All the structural changes caused by those free radicals will lead to not only endoplasmic reticulum modification but also protein synthesis reduction. The cytoplasmic membrane lipids damage will eventually cause an increase in hepatic serum markers, namely ALT, AST, and ALP. Therefore those enzymes utilized as biochemical markers for chemicals or drug-induced liver injury in a clinical setting. Some previous study pointed a decrease in those enzymes while hepatocurative substance or antioxidants were given to CCl₄-induced animals (Abou Seif, 2016; Manfo *et al.*, 2014; Reyes-Gordillo *et al.*, 2012).

Effects of C-MSN on a hepatic biochemical marker

ALT, AST, and ALP level in the curcumin group were lower than the CCl₄ control group although the decrease only significant in the ALT group (49%, 51%, 4% lower; $p < 0.05$) (Table I). Curcumin can reduce oxidative stress, and therefore it has a protective effect on the liver. It inhibits NF-κB activity, proinflammatory cytokines, liver tissue morphology and HSC (primary fibrogenic cells in the liver) activation (Farzaei *et al.*, 2018). Curcumin has a potential counter effect on CCl₄ toxicity by preventing biliary cirrhosis and also reverse fibrosis that has been recognized. Fibrogenesis of liver cells was

inhibited by lowering TLR2, TLR4, and HMGB1 expression, inhibiting of proinflammatory mediators and HSC activation. Curcumin is also reducing the α-smooth muscle actin (α-SMA) expression and deposition of collagen to relieve liver fibrosis and necrosis and inflammation of the liver. Curcumin also significantly attenuates the molecular expression of Smad2, phosphorylated Smad2, Smad3, TGF-β, and connective tissue growth factor (CTGF). It also induced the expression of the Smad7. Therefore, it can be said that curcumin decreases fibrosis by inhibiting the TGF-β1/Smad signalling pathway and CTGF expression (Reyes-Gordillo *et al.*, 2012).

C-MSN showed a slightly better hepatoprotective effect evidenced by lower serum ALT (3.2% lower) and AST (55% lower) than the curcumin group. Although there is a mixed type of hepatic damage, there are two main types of liver damage which are hepatocellular (predominantly first ALT elevation) and cholestatic (initial ALP rise). AST has a catalyzer property to the conversion process from alanine to pyruvate and glutamate. AST could be an indicator of liver damage that causes by viral hepatitis, cardiac infarction, and liver injury. Lesser degrees of increasing ALT level was shown in such condition; therefore ALT is more specific to the liver and could be a better parameter for detecting liver injury.

Meanwhile, serum ALP is related to hepatic cell function. An increase in serum ALP is due to increased synthesis as a result of the increase in biliary pressure (Abou Seif, 2016). Although serum ALP was not significantly different between curcumin and C-MSN group (724±116U/L vs 819±58U/L; $p > 0.05$), histology of the liver cells (Figure 1) showed an excellent protective effect on the liver cells.

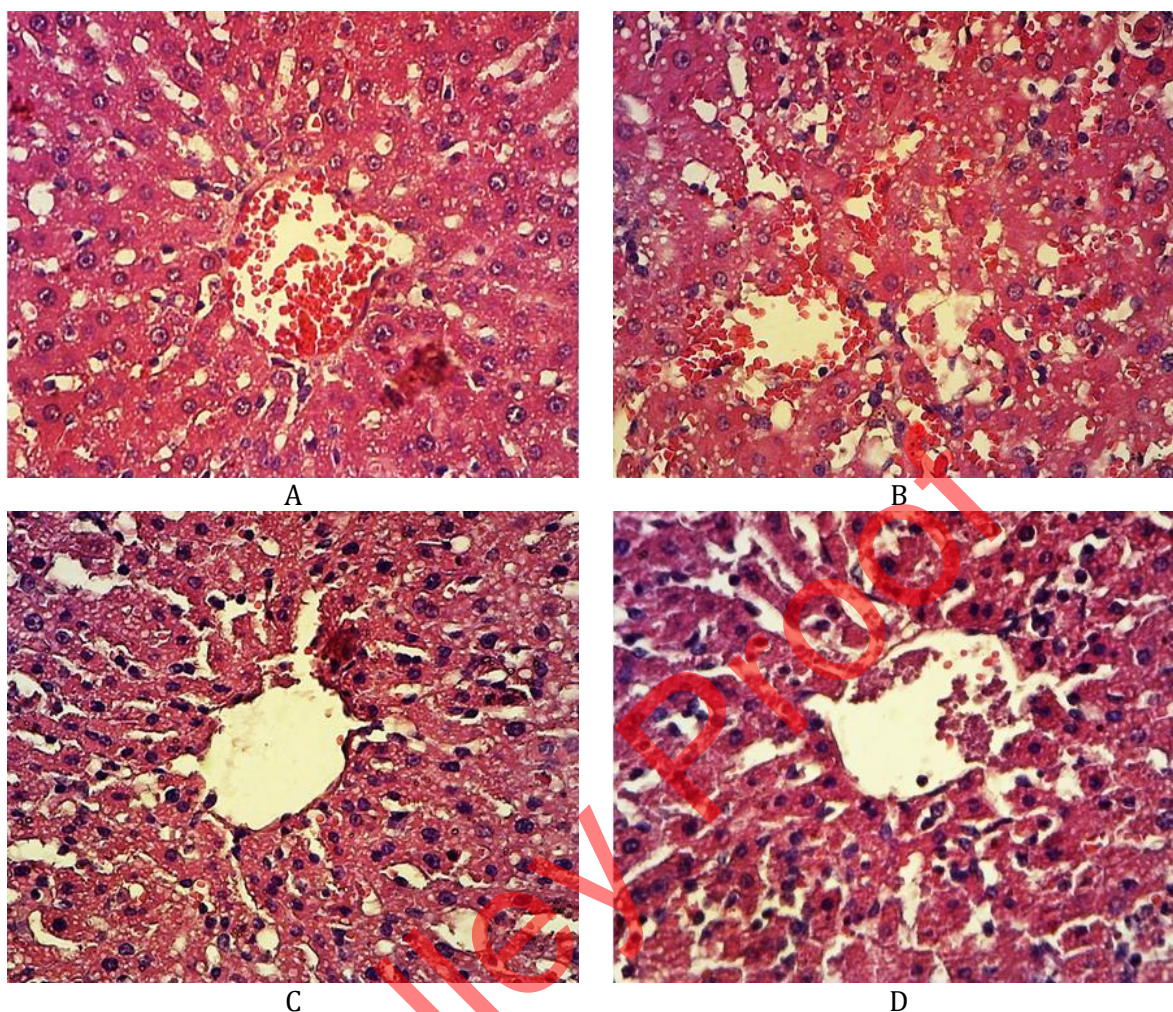


Figure 1. Histology of liver rat cells in CCl₄-induced rats in normal group (A), CCl₄-induced rats (B), curcumin (C), C-MSN (D) (H&E staining, 400x magnification).

Effects of C-MSN on hepatic histopathological morphology

The histology of liver rat cells in normal group showed that the number of necrotic hepatic cells and the degenerated cells were lower than the other group (Figure 1A).

CCl₄ caused a significant increase in necrotic and degenerated cells (Table II). The number of necrotic and degenerated cells were 12 and 3.5 times higher respectively. Various cells showed hydropic degeneration with swelling cells, cytoplasm filled with clear vacuoles which can be composed of fat, water, or glycogen (Figure 1B). Those clear vacuoles can push away the cell nucleus to the edge. Some cells were showed fatty degeneration with swelling cells and clear fat vacuoles. Necrotic cells were found dominantly in

three different types, pyknosis cells, karyorrhexis cells, and karyolysis cells. Hepatic lobular disorganization was also very obvious. However, rats pre-treated with curcumin (Figure 1C) and C-MSN (Fig. 1D) has a lower number of necrotic liver cells ($p < 0.05$). A good hepatoprotective effect of C-MSN was in line with our result from the previous study that C-MSN has a good release profile, a higher solubility, and bioavailability than free curcumin. C-MSN has a cubic mesostructure and 3D interconnected pores, large pore size, and reduced diffusion length. Together with amine functionalization, C-MSN has a fast and higher release of curcumin in a sustained manner. It has a better dissolution rate and a higher bioavailability so that it can protect the liver more effectively than free curcumin (Hartono *et al.*, 2016).

Table II. Effect of curcumin and C-MSN on hepatic cells.

Group	Necrotic Hepatic Cells	Degenerated Hepatic Cells
Normal	16±2 ^d	57±8 ^b
CCl ₄ Control	198±3 ^a	202±9 ^a
Curcumin	80±16 ^c	159±40 ^a
C-MSN	147±9 ^b	213±22 ^a

Data express the mean ± S.E.M cells for four rats (percentage from 500 cells). Means sharing a different subscript in a column are significantly different (LSD multiple comparison test, $p < 0.05$).

A significant decrease in necrotic and degenerated cells was found in the curcumin group rather than in the C-MSN group. Otherwise, C-MSN group turned to have a higher necrotic and degenerated cells. It was already known that curcumin has an excellent protective effect against liver fibrosis by inhibiting HIF-1 α through an ERK-dependent pathway (Marslin *et al.*, 2018). It was interesting that C-MSN group showed a higher number of necrotic cells compared with curcumin group although it was not statistically significant. That phenomenon led to the emergence of suspicion towards MSN toxicity. It has been reported that shapes influenced the toxicity of MSN. There was an increase in silica content in the liver at seven days after 40mg/kg b.w. spherical shape MSN oral administration. This trend was in opposition with shot and long rod shape of MSN. However, there was no significant increase in hepatic enzyme markers or liver histological micro-morphology damage at 14 days after administration of MSN with various shape. Also, renal tubular impairment was found in that study (Li *et al.*, 2015). One previous study had been reported no toxicity after 90 days oral administration of colloidal silica nanoparticles (20 and 100 nm size) given at 2000mg/kg dose (Kim *et al.*, 2014). Another study reporting hepatic toxicity with mononuclear infiltrate at the portal area and hepatocyte necrosis at the portal triads of the liver at 30 days after MSN (10mg/kg) IV administration (Xie *et al.*, 2010). To date, there was no report regarding the oral toxicity of cubical MSN used in this study. So further study is needed.

CONCLUSION

C-MSN used in this study showed excellent hepatoprotective properties with a significant decreasing number of necrotic cells compare with CCl₄ control group (2.6% lower; $p < 0.05$). C-MSN is a promising compound to be formulated as a

hepatoprotective agent. However, an oral toxicity study of MSN must be carried out first to determine its toxicity.

ACKNOWLEDGEMENT

We acknowledge the support from the Ministry of Research, Technology and Higher Education of Indonesia for providing a research grant under the national competition scheme (HIKOM 2017).

REFERENCES

- Abou Seif, HS., 2016. Physiological changes due to hepatotoxicity and the protective role of some medicinal plants. Beni-Suef Univ. J. Basic Appl. Sci. 5(2): 134–146. doi:10.1016/j.bjbas.2016.03.004
- Adaramoye, OA., Odunewu, AO., Farombi, EO., 2010. Hepatoprotective effect of Curcuma longa L. in D-galactosamine induced liver injury in mice: evidence of antioxidant activity. Afr. J. Med. Med. Sci. 39 Suppl 27–34.
- Amdalia, PR., Anwar, C., Kurnijasanti, R., 2017. Pengaruh Pemberian Ekstrak Daun Kelor (Moringa oleifera) terhadap Gambaran Histopatologi Sel Hepar Mencit Jantan yang Dipapar Metilmerkuri. J. Basic Med. Vet. 6(1): 1–7.
- Černý, D., Lekić, N., Váňová, K., Muchová, L., Hořínek, A., Kmoníčková, E., Zídek, Z., Kameníková, L., Farghali, H., 2011. Hepatoprotective effect of curcumin in lipopolysaccharide/-galactosamine model of liver injury in rats: Relationship to HO-1/CO antioxidant system. Fitoterapia. 82(5): 786–791. doi:10.1016/j.FITOTE.2011.04.003
- Farida, Y., Andayani, TM., Ratnasari, N., 2013. Analisis penggunaan obat pada komplikasi sirosis hati. J. Manaj. dan Pelayanan Farm. 4(2): 77–84.

- Farzaei, M., Zobeiri, M., Parvizi, F., El-Senduny, F., Marmouzi, I., Coy-Barrera, E., Naseri, R., Nabavi, S., Rahimi, R., Abdollahi, M., 2018. Curcumin in Liver Diseases: A Systematic Review of the Cellular Mechanisms of Oxidative Stress and Clinical Perspective. *Nutrients*. 10(7): 855. doi:10.3390/nu10070855
- Girish, C., Pradhan, SC., 2012. Hepatoprotective activities of picroliv, curcumin, and ellagic acid compared to silymarin on carbon-tetrachloride-induced liver toxicity in mice. *J. Pharmacol. Pharmacother.* 3(2): 149–55. doi:10.4103/0976-500X.95515
- Hartono, SB., Hadisoewignyo, L., Yang, Y., Meka, AK., Antaresti, Yu, C., 2016. Amine functionalized cubic mesoporous silica nanoparticles as an oral delivery system for curcumin bioavailability enhancement. *Nanotechnology*. 27(50): 505605. doi:10.1088/0957-4484/27/50/505605
- Hismiogullari, SE., Hismiogullari, AA., Sunay, FB., Paksoy, S., Can, M., Aksit, H., Karaca, O., 2014. The protective effect of curcumin on carbon tetrachloride induced liver damage. *Rev. Med. Vet. (Toulouse)*. 7–8(165): 194–200.
- Kim, Y., You, Y., Yoon, H., Lee, Y-H., Kim, K., Lee, J., Kim, MS., Kim, J., Jun, W., 2014. Hepatoprotective effects of fermented *Curcuma longa* L. on carbon tetrachloride-induced oxidative stress in rats. *Food Chem.* 151 148–153. doi:10.1016/j.foodchem.2013.11.058
- Kim, YR., Lee, SY., Lee, EJ., Park, SH., Seong, NW., Seo, HS., Shin, SS., Kim, SJ., Meang, EH., Park, MK., Kim, MS., Kim, CS., Kim, SK., Son, SW., Seo, YR., Kang, BH., Han, BS., An, SSA., Lee, BJ., Kim, MK., 2014. Toxicity of colloidal silica nanoparticles administered orally for 90 days in rats. *Int. J. Nanomedicine*. 9(December): 67–78. doi:10.2147/IJN.S57925
- Lee, G-H., Lee, H-Y., Choi, M-K., Chung, H-W., Kim, S-W., Chae, H-J., 2017. Protective effect of *Curcuma longa* L. extract on CCl₄-induced acute hepatic stress. *BMC Res. Notes*. 10(1): 77. doi:10.1186/s13104-017-2409-z
- Li, L., Liu, T., Fu, C., Tan, L., Meng, X., Liu, H., 2015. Biodistribution, excretion, and toxicity of mesoporous silica nanoparticles after oral administration depend on their shape. *Nanomedicine Nanotechnology, Biol. Med.* 11(8): 1915–1924. doi:10.1016/j.nano.2015.07.004
- Manfo, FPT., Nantia, EAN., Kuete, V., 2014. Toxicological Survey of African Medicinal Plants., in: Kuete, V. (Ed.), *Toxicological Survey of African Medicinal Plants*. Elsevier, London, pp. 323–355. doi:10.1016/C2013-0-15406-2
- Marslin, G., Prakash, J., Qi, S., Franklin, G., 2018. Oral delivery of curcumin polymeric nanoparticles ameliorates CCl₄-induced subacute hepatotoxicity in wistar rats. *Polymers (Basel)*. 10(5):. doi:10.3390/polym10050541
- Nayak, A., Raikar, A., Kotrashetti, V., Nayak, R., Shree, S., Kambali, S., 2016. Histochemical detection and comparison of apoptotic cells in the gingival epithelium using hematoxylin and eosin and methyl green-pyronin: A pilot study. *J. Indian Soc. Periodontol.* 20(3): 294–8. doi:10.4103/0972-124X.182601
- Omosa, LK., Midiwo, JO., Kuete, V., 2017. *Curcuma longa*, in: Kuete, V. (Ed.), *Medicinal Spices and Vegetables From Africa*. Elsevier Inc., London, pp. 425–435.
- Paolo, P., Kateri, Y., 2017. TESIS Título : “ Efecto hepatoprotector del extracto acuoso liofilizado de *Curcuma longa* L . en daño hepático agudo inducido por tetracloruro de carbono en ratas albinas ”. TESIS : TÍTULO : “ Efecto hepatoprotector del extracto acuoso liofilizado de *Curcu*.”
- Park, E., Jeon, CH., Ko, G., Kim, J., Sohn, DH., Al, EPET., 2000. Protective Effect of Curcumin in Rat Liver Injury Induced by Carbon Tetrachloride. 437–440.
- Reyes-Gordillo, K., Shah, R., Lakshman, MR., Flores-Beltrán, RE., Muriel, P., 2012. Hepatoprotective Properties of Curcumin., in: Muriel, P. (Ed.), *Liver Pathophysiology: Therapies and Antioxidants*. Elsevier Inc., London, pp. 687–704.
- Saygili, OK., Paksoy, S., Hismiogullari, SE., Kus, MA., Sunay, FB., Gulcen, B., Ozcan, E., 2016. Prevention of Carbon Tetrachloride-Induced Liver Injury in Rats by Omega-3 Fatty Acids. *Acta Medica Mediterr.* 33 137–144. doi:10.19193/0393-6384_2017_1_021
- Sengupta, M., Sharma, GD., Chakraborty, B., 2011. Hepatoprotective and immunomodulatory properties of aqueous extract of *Curcuma longa* in carbon tetra chloride intoxicated Swiss albino mice. *Asian Pac. J. Trop. Biomed.* 1(3): 193–199. doi:10.1016/S2221-1691(11)60026-9
- Singh, N., Khullar, N., Kakkar, V., Kaur, IP., 2014.

- Attenuation of carbon tetrachloride-induced hepatic injury with curcumin-loaded solid lipid nanoparticles. *BioDrugs*. 28(3): 297–312. doi:10.1007/s40259-014-0086-1
- Song, E-K., Cho, H., Kim, J-S., Kim, N-Y., An, N-H., Kim, J-A., Lee, S-H., Kim, Y-C., 2001. Diarylheptanoids with Free Radical Scavenging and Hepatoprotective Activity in vitro from *Curcuma longa*. *Planta Med*. 67(9): 876–877. doi:10.1055/s-2001-18860
- Tandi, J., 2017. Pola Penggunaan Obat Pada Pasien Penyakit Hati Yang Menjalani Rawat Inap Di Rumah Sakit Umum Daerah Undata Palu. *J. Pengemb. Sumber Daya Insa*. 02(02): 218–223.
- Virgonita, S., Karim, A., 2012. Pola Penggunaan Obat pada Pasien Sirosis Hati di Instalasi Rawat Inap Bangsal Penyakit Dalam Rumah Sakit Dr . Sardjito Yogyakarta CIRRHOSIS IN INTERNAL DISEASE WARD INPATIENT OF. *Maj. Farm*. 8(3): 218–226.
- Wu, S-J., Lin, Y-H., Chu, C-C., Tsai, Y-H., Chao, J-C-J., 2008. Curcumin or Saikosaponin a Improves Hepatic Antioxidant Capacity and Protects Against CCl₄ -Induced Liver Injury in Rats. *J. Med. Food*. 11(2): 224–229. doi:10.1089/jmf.2007.555
- Xie, G., Sun, J., Zhong, G., Shi, L., Zhang, D., 2010. Biodistribution and toxicity of intravenously administered silica nanoparticles in mice. *Arch. Toxicol*. 84(3): 183–190. doi:10.1007/s00204-009-0488-x
- Zhao, Y., Ma, X., Wang, J., He, X., Hu, Y., Zhang, P., Wang, R., Li, R., Gong, M., Luo, S., Xiao, X., 2014. Curcumin protects against ccl₄-induced liver fibrosis in rats by inhibiting HIF-1 α through an erk-dependent pathway. *Molecules*. 19(11): 18767–18780. doi:10.3390/molecules191118767

Galley Proof

Hepatoprotective effects of Curcumin-Mesoporous Silica Nanoparticles on CCl₄-induced Hepatotoxicity Wistar rats

Lannie Hadisoewignyo^{1*}, Ivonne Soeliono¹, Sandy Budi Hartono², Eka Pramhyrta Hestianah³, and Sri Rahayu Mahanani¹

1. Faculty of Pharmacy, Widya Mandala Catholic University Surabaya, Jalan Raya Kalisari Selatan No. 1, Pakuwon City, Surabaya, Indonesia, 60112
2. Faculty of Engineering, Widya Mandala Catholic University Surabaya, Jalan Kalijudan No. 37, Surabaya, Indonesia, 60114
3. Faculty of Veterinary Medicine, Airlangga University, Campus C, Mulyorejo, Surabaya, 60115

Info Article	ABSTRACT
<p>Submitted: 26-01-2019</p> <p>Revised: 27-05-2019</p> <p>Accepted: 29-05-2019</p> <p>*Corresponding author Lannie Hadisoewignyo</p> <p>Email: lanhadi@yahoo.com</p>	<p>It has been reported that curcumin has a hepatoprotective effect, but its low solubility limited its utilization. Recently there was so many emerging research of advanced curcumin formulation, such as nanoparticles curcumin. In our previous study, curcumin has been loaded into mesoporous silica nanoparticles (C-MSN). This study was performed both to evaluate of C-MSN hepatoprotective effect in CCl₄-induced rats. Sixteen rats were divided into four groups, namely normal and CCl₄ control, curcumin, C-MSN group. Treatment was given according to its group for fourteen days consecutively. At day 14, three hours after the last administration, CCl₄ (1.25mL/kgBB) were administered orally. Twelve hours later the rats were sacrificed, and blood samples were drawn from their hearts. Blood serum examination result revealed that C-MSN caused a significantly lower ALT and AST than CCl₄ control group (851±271U/L vs 1734±275U/L; 295±155U/L vs 1348±235U/L; p<0.05). Its effect on hepatic serum level resembled curcumin group. However, the result was not supported by histology examination which showed a higher number of necrotic hepatic cells in C-MSN group than in the curcumin group (147±9 vs 80±16; p<0.05). From this study, it can be concluded that C-MSN revealed an excellent hepatoprotective property, but it was suspected that MSN itself has the toxic effect on the liver. A further study of MSN toxicity was needed to support its safety use.</p> <p>Keywords: curcumin, curcumin nanoparticles, hepatoprotection, carbon tetrachloride.</p>

INTRODUCTION

Curcuma longa L. (Zingiberaceae) or turmeric is used widely in Indonesia as food spices. However, turmeric has potential as a medicine, beauty aid, cooking spice, and as a dye (Omosa *et al.*, 2017). *C. longa* contains curcumin, a natural polyphenol, and a primary yellow pigment. Curcumin is one of the curcuminoids in the rhizome that has many activities such as hepatoprotective, antioxidant, antineoplastic, antibacterial, antiviral, antifungal, anti-inflammatory, antidiabetic, anticoagulant, antifertility, cardiovascular protective, and immunostimulant activity. Therefore, curcumin is believed as one of the

constituents responsible for bioactivities of the rhizome of this plant.

In several previous studies, *C. longa* was reported to have a hepatoprotective effect against CCl₄ hepatic damage induction (Girish and Pradhan, 2012; Hismiogullari *et al.*, 2014; Kim *et al.*, 2014; Lee *et al.*, 2017; Marslin *et al.*, 2018; Paolo and Kateri, 2017; Park *et al.*, 2000; Saygili *et al.*, 2016; Singh *et al.*, 2014; Wu *et al.*, 2008; Zhao *et al.*, 2014). Fermented *C. longa* is showing a hepatoprotective effect by suppressing oxidative stress caused by CCl₄ (Kim *et al.*, 2014). *C. longa* (30, 300mg/kg b.w.) given orally for 14 days has inhibited alanine aminotransferase (ALT),

aspartate aminotransferase (AST), alkaline phosphatase (ALP), and lactate dehydrogenase (LDH) (Kim *et al.*, 2014). It also enhanced antioxidant activities so that it was suitable as a candidate for various liver diseases prevention associated with oxidative stress (Kim *et al.*, 2014). Aqueous extract of *C. longa* also reported having amelioration property to CCl₄-induced hepatotoxicity in Swiss albino mice (Sengupta *et al.*, 2011). Its methanol extract also showed an ameliorating effect on galactosamine-induced liver injury in mice (Adaramoye *et al.*, 2010). Its ethanol soluble fraction also has been proven to have a hepatoprotective effect on tacrine-induced cytotoxicity in human liver-derived HepG2 cells (Song *et al.*, 2001). Curcumin hepatoprotective activities were also evidenced in lipopoly-saccharide/d-galactosamine model of liver injury in rats. It decreases ALT and AST levels as well as lipid peroxidation activities (Černý *et al.*, 2011).

In the clinical setting, the use of curcumin as hepatoprotection agent in the patient with liver cirrhosis has been a standard clinical treatment in an Indonesian hospital. Nowadays, the use of curcumin as one of the liver cirrhosis therapy is also an increasing trend (Farida *et al.*, 2013; Tandi, 2017; Virgonita and Karim, 2012). However, the effectiveness of curcumin as a drug is limited by its chemical properties. Curcumin has low bioavailability because it has negligible solubility in water and only limited solubility in ethanol or acetone. Some researchers prepare an innovative breakthrough by loading curcumin into nanoparticles. Some previous hepatoprotective study showed that curcumin nanoparticles also have hepatoprotection effect, even better than curcumin. Solid lipid nanoparticles loaded with curcumin (C-SLN; 12.5mg/kg b.w.) given daily for four weeks showing a significant effect as an antioxidant and as a protector of liver damage in CCl₄ subchronic induction. C-SLN has a 62.07 and 83.37% inhibition of hepatic impairment resulting in 2.63 and 6.01 fold alleviation in ALT and AST values, respectively (Singh *et al.*, 2014). Curcumin also has been loaded in nanoparticles prepared from PLGA and PVA was given four times a week with CCl₄ given two times a week. That curcumin nanoparticles showed a good hepatoprotection effect as AST, ALT, and ALP value was decreased, and no damage was found in liver tissue treated with nano-curcumin (Marslin *et al.*, 2018).

In our previous research curcumin has been loaded into mesoporous silica nanoparticles (C-MSN). It has been proven that C-MSN has a higher

bioavailability than 'free curcumin' (Hartono *et al.*, 2016) so that it was expected to have a better hepatoprotection activity. In the present study, the C-MSN hepatoprotective effect will be evaluated against curcumin. To best of our knowledge, this is the first report of cubical curcumin-amine functionalized mesoporous silica nanoparticles (C-MSN) hepatoprotection effect.

MATERIAL AND METHODS

Sample and chemicals

Curcuma longa L. dry extract was purchased from and certified by Java Plants (Solo, Indonesia). C-MSN was prepared according to the method described by Hartono *et al.* (2016). Materials for C-MSN hepatoprotective study are carbon tetrachloride (E-Merck, Germany), corn oil (PT. Jaya Utama Santika, Indonesia), formaldehyde (Sigma Aldrich, Singapore), monosodium and disodium phosphate ~~and~~ (PT. Labtech Citra Persada, Indonesia), alcohol 96% (Sigma Aldrich, Singapore), sodium carboxymethylcellulose 0.5% as vehicles (Sigma Aldrich, Singapore), sterile sodium chloride 0.9% (Otsuka, Indonesia), water for injection (Otsuka, Indonesia).

Animals

Eight until twelve-week-old male Wistar rats (*Rattus norvegicus*) with body weight (b.w.) of 109-127g were obtained from a veterinarian breeder. All animals transferred into the animal laboratory in Widya Mandala Catholic University, Surabaya, Indonesia to be acclimatized for seven days. Rats were housed under 12h light/dark cycle and fed with standard laboratory diet and water ad libitum. Ethical approval was requested from the Animal Ethics Committee at Gadjah Mada University, Yogyakarta, Indonesia (Certificate no: 00108/04/LPPT/XII/2018).

C-MSN preparation

MSN preparation was done using a method published in our previous paper. 0.5g of triblock poly(ethylene oxide)-b-poly(propylene oxide)-b-poly(ethylene oxide) copolymer EO₁₀₆PO₇₀EO₁₀₆ (Pluronic® F127, MW=12600) and 1.4 of fluorocarbon surfactant (FC-4) mixed in the solutions of 60mL of 0.02M HCl then 0.5g of 1,3,5-trimethylbenzene (TMB) was added. Tetraethoxysilane (TEOS, 99%) was added after four h stirring and continued for 24h at 20°C. The substance was heated at 130°C for 24h in an autoclave then it was separated, washed and dried. Its surfactant was removed by calcination at 550°C

for six h. Amine functionalization was performed by grafting method where 0.6g of mesoporous silica (MSN) was added into 30mL toluene. It was stirred and heated to 70°C, and 1.2mL of 3-aminopropyltriethoxysilane (APTES, 99%) was added into the mixture, then the stirring was continued for 20h. The substance then centrifuged and dried. After the MSN was ready, curcumin was loaded into MSN. 50mg of curcumin and 200mg of MSN was mixed within a rotary evaporation flask. After added 20mL of ethanol, the mixture was sonicated for 2min with a Bath sonicator. Ethanol was evaporated slowly under vacuum at a temperature of 55°C. Finally, curcumin loaded MSN was obtained (Hartono *et al.*, 2016).

Experimental groups determination

The method used in this study refers to the hepatoprotective testing method from Kim *et al.* (2014). There were four animal groups in this experiment. Each group was consists of four animals. The animal was grouped randomly with regards to minimalized body weight variation within the group. All substances were administered by gastric intubation. The administration was done continuously for 14 days daily. The curcumin group was administered 2mg/kg b.w. Curcumin. The C-MSN group was administered 10mg/kg b.w. C-MSN. Curcumin and C-MSN powder were prepared in mucilage form with 0.5% CMC-Na. The normal and CCl₄ control group rats were administered only 0.5% CMC-Na. At day 14, three hours after last administration, curcumin, C-MSN, and CCl₄ control group were administrated CCl₄ 1.25mL/kg b.w, dissolved in 20% corn oil. CCl₄ was administered using gastric intubation method. The control group rats were only given 20% corn oil. Rats were anesthetized 12h after CCl₄ treatment under ketamine 40mg/kg b.w. and xylazine 7mg/kg b.w. (intraperitoneally) to collect the blood sample. After the blood sample was taken from the heart, cervical dislocation and abdominal incision were performed to collect liver from the rats.

Hepatic enzymes analysis

Blood samples collected from rats were centrifuged to separate sera. Sera were prepared for analysis according to the manual procedure of biochemical autoanalyzer (Prestige 24i Tokyo-Boeki, Japan). International Federation of Clinical Chemistry (IFCC) method was performed to determine aspartate aminotransferase (AST),

alanine aminotransferase (ALT) and alkaline phosphatase (ALP) level.

Histology examination of the liver

All portions of the liver were fixed in 10% buffered formalin solution for 24h and then trimmed. The liver tissue (n=4/ group) were gradually dehydrated in 70% alcohol, 80% alcohol, 90% alcohol, 96% alcohol, xylol, and liquid paraffin. Next step is tissue vacuuming and embedding. Liver tissue was sectioned at a thickness of 4-6μm and then processed with hematoxylin and eosin staining. Tissue was observed under a microscope (Olympus CX-21, Japan with Optilab® Advanced Plus, Indonesia) with 400 times magnification. Five hundred cells were counted for each preparation slide, and those cells were classified into normal, degenerated, and necrotic cells (Amdalia *et al.*, 2017).

The H&E stained sections were evaluated under light microscopy. Five hundred cells were counted in five visual fields (from the upper left of the to the right direction of preparation). Those cells were then classified into normal, degenerated, and necrotic cells (including karyopyknotic, karyorrhexis, and karyolysis cells) (Amdalia *et al.*, 2017; Nayak *et al.*, 2016).

Statistical analysis

ALT, AST, ALP, number of necrotic and degenerated liver cells are presented as mean ± SD of 4 replicates. All data were statistically analyzed using IBM SPSS Statistics for Windows, Version 24.0 (IBM Corp., USA). After testing the normality of the data distribution using a Shapiro-Wilk test, one-way analysis of variance (ANOVA) was performed. LSD multiple comparisons were performed as a post-hoc test to see any significant differences between each group. A 0.05 level was adopted for any significant difference.

RESULT AND DISCUSSION

Carbon tetrachloride (CCl₄) induced a very significant increase in ALT, AST, ALP (p<0.05), namely 29, 9, and two times of normal control group value, due to severe damage of the liver cells (Table I). This result is in line with the previous study result that supports CCl₄ as a preferred chemical compound to induce animal hepatic cell damage. (Girish and Pradhan, 2012; Hismiogullari *et al.*, 2014; Y. Kim *et al.*, 2014; Lee *et al.*, 2017; Marslin *et al.*, 2018; Paolo and Kateri, 2017; Park *et al.*, 2000; Saygili *et al.*, 2016; Singh *et al.*, 2014;

Table I. Effect of curcumin and C-MSN on hepatic serum markers of CCl₄-induced rats.

Group	ALT (U/L)	AST (U/L)	ALP (U/L)
Normal control	59±2 ^c	153±21 ^b	435±78 ^b
CCl ₄ control	1734±275 ^a	1348±235 ^a	754±74 ^a
Curcumin	879±272 ^b	656±358 ^{ab}	724±116 ^a
C-MSN	851±271 ^b	295±155 ^b	819±58 ^a

Data express the mean ± S.E.M for four rats (in units/liter). AST, aspartate aminotransferase; ALT, alanine aminotransferase; ALP, alkaline phosphatase. Means sharing a different subscript in a column are significantly different (LSD multiple comparison test, $p < 0.05$).

Wu *et al.*, 2008; Zhao *et al.*, 2014). Hepatic damage induction using CCl₄ it is easily reproducible, and it simulates human liver cirrhosis quite well by the generation of oxidative stress and induces proinflammatory and profibrotic cytokines. CCl₄ is converted into CCl₃· in the liver. Its exposure to O₂ result in CCl₃· transformation to CCl₃O₂·. CCl₃· and CCl₃O₂· are highly reactive to bind to lipid and protein. Those radicals could remove a hydrogen atom from unsaturated lipids and causes lipid peroxidation. All the structural changes caused by those free radicals will lead to not only endoplasmic reticulum modification but also protein synthesis reduction. The cytoplasmic membrane lipids damage will eventually cause an increase in hepatic serum markers, namely ALT, AST, and ALP. Therefore those enzymes utilized as biochemical markers for chemicals or drug-induced liver injury in a clinical setting. Some previous study pointed a decrease in those enzymes while hepatocurative substance or antioxidants were given to CCl₄-induced animals (Abou Seif, 2016; Manfo *et al.*, 2014; Reyes-Gordillo *et al.*, 2012).

Effects of C-MSN on a hepatic biochemical marker

ALT, AST, and ALP level in the curcumin group were lower than the CCl₄ control group although the decrease only significant in the ALT group (49%, 51%, 4% lower; $p < 0.05$) (Table I). Curcumin can reduce oxidative stress, and therefore it has a protective effect on the liver. It inhibits NF-κB activity, proinflammatory cytokines, liver tissue morphology and HSC (primary fibrogenic cells in the liver) activation (Farzaei *et al.*, 2018). Curcumin has a potential counter effect on CCl₄ toxicity by preventing biliary cirrhosis and also reverse fibrosis that has been recognized. Fibrogenesis of liver cells was

inhibited by lowering TLR2, TLR4, and HMGB1 expression, inhibiting of proinflammatory mediators and HSC activation. Curcumin is also reducing the α-smooth muscle actin (α-SMA) expression and deposition of collagen to relieve liver fibrosis and necrosis and inflammation of the liver. Curcumin also significantly attenuates the molecular expression of Smad2, phosphorylated Smad2, Smad3, TGF-β, and connective tissue growth factor (CTGF). It also induced the expression of the Smad7. Therefore, it can be said that curcumin decreases fibrosis by inhibiting the TGF-β1/Smad signalling pathway and CTGF expression (Reyes-Gordillo *et al.*, 2012).

C-MSN showed a slightly better hepatoprotective effect evidenced by lower serum ALT (3.2% lower) and AST (55% lower) than the curcumin group. Although there is a mixed type of hepatic damage, there are two main types of liver damage which are hepatocellular (predominantly first ALT elevation) and cholestatic (initial ALP rise). AST has a catalyzer property to the conversion process from alanine to pyruvate and glutamate. AST could be an indicator of liver damage that causes by viral hepatitis, cardiac infarction, and liver injury. Lesser degrees of increasing ALT level was shown in such condition; therefore ALT is more specific to the liver and could be a better parameter for detecting liver injury.

Meanwhile, serum ALP is related to hepatic cell function. An increase in serum ALP is due to increased synthesis as a result of the increase in biliary pressure (Abou Seif, 2016). Although serum ALP was not significantly different between curcumin and C-MSN group (724±116U/L vs 819±58U/L; $p > 0.05$), histology of the liver cells (Figure 1) showed an excellent protective effect on the liver cells.

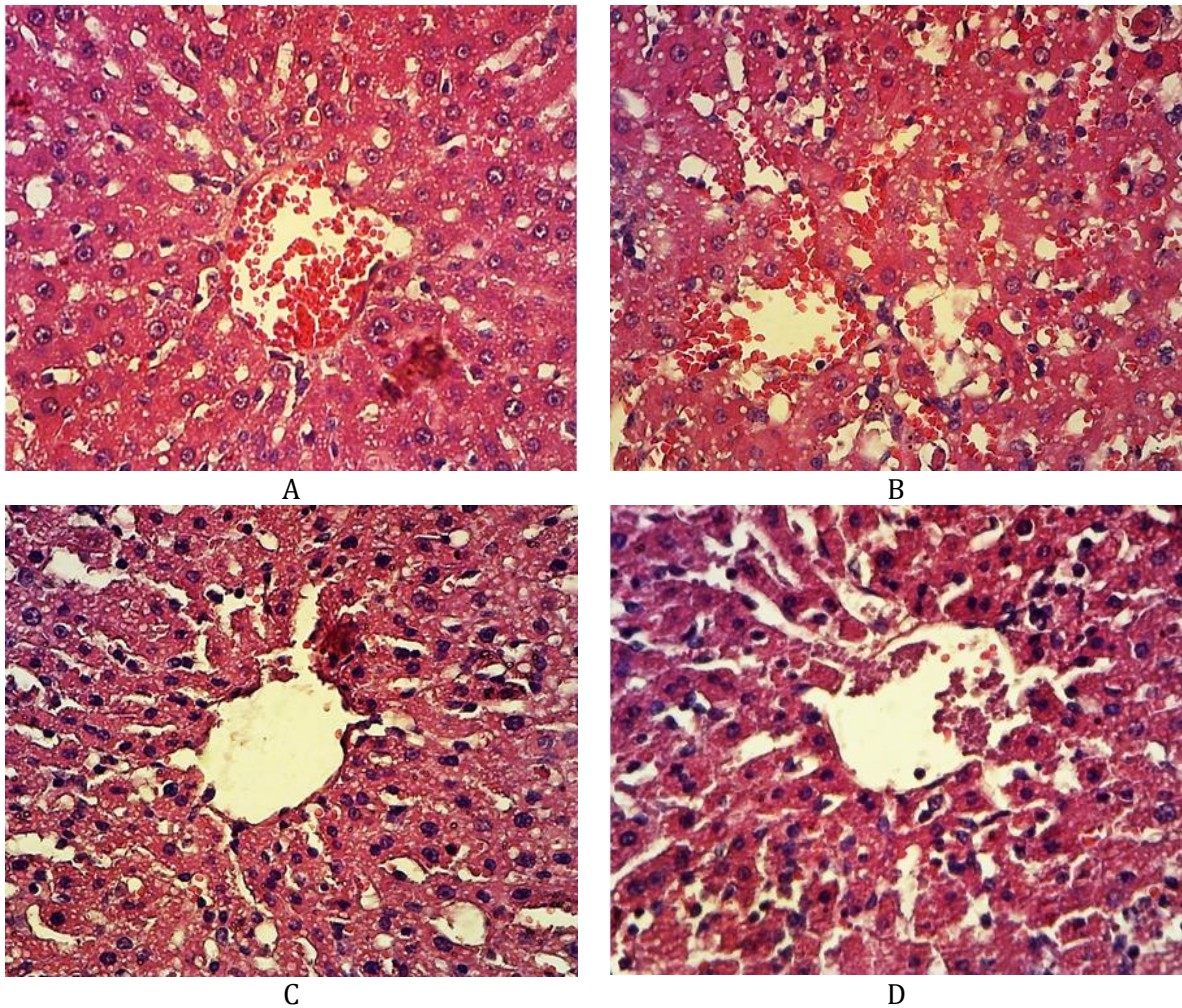


Figure 1. Histology of liver rat cells in CCl₄-induced rats in normal group (A), CCl₄ control group (B), curcumin group (C), C-MSN group (D) (H&E staining, 400x magnification).

Effects of C-MSN on hepatic histopathological morphology

The histology of liver rat cells in normal group showed that the number of necrotic hepatic cells and the degenerated cells were lower than the other group (Figure 1A).

CCl₄ caused a significant increase in necrotic and degenerated cells (Table II). The number of necrotic and degenerated cells were 12 and 3.5 times higher, respectively. Various cells showed hydropic degeneration with swelling cells, cytoplasm filled with clear vacuoles, which can be composed of fat, water, or glycogen (Figure 1B). Those clear vacuoles can push away the cell nucleus to the edge. Some cells were showed fatty degeneration with swelling cells and clear fat vacuoles. Necrotic cells were found dominantly in

three different types, pyknosis cells, karyorrhexis cells, and karyolysis cells. Hepatic lobular disorganization was also very obvious. However, rats pre-treated with curcumin (Figure 1C) and C-MSN (Figure 1D) has a lower number of necrotic liver cells ($p < 0.05$). A good hepatoprotective effect of C-MSN was in line with our result from the previous study that C-MSN has a good release profile, a higher solubility, and bioavailability than free curcumin. C-MSN has a cubic mesostructure and 3D interconnected pores, large pore size, and reduced diffusion length. Together with amine functionalization, C-MSN has a fast and higher release of curcumin in a sustained manner. It has a better dissolution rate and a higher bioavailability so that it can protect the liver more effectively than free curcumin (Hartono *et al.*, 2016).

Table II. Effect of curcumin and C-MSN on hepatic cells.

Group	Necrotic Hepatic Cells	Degenerated Hepatic Cells
Normal	16±2 ^d	57±8 ^b
CCl ₄ Control	198±3 ^a	202±9 ^a
Curcumin	80±16 ^c	159±40 ^a
C-MSN	147±9 ^b	213±22 ^a

Data express the mean ± S.E.M cells for four rats (percentage from 500 cells). Means sharing a different subscript in a column are significantly different (LSD multiple comparison test, $p < 0.05$).

A significant decrease in necrotic and degenerated cells was found in the curcumin group rather than in the C-MSN group. Otherwise, C-MSN group turned to have a higher necrotic and degenerated cells. It was already known that curcumin has an excellent protective effect against liver fibrosis by inhibiting HIF-1 α through an ERK-dependent pathway (Marslin *et al.*, 2018). It was interesting that C-MSN group showed a higher number of necrotic cells compared with curcumin group, although it was not statistically significant. That phenomenon led to the emergence of suspicion towards MSN toxicity. It has been reported that shapes influenced the toxicity of MSN. There was an increase in silica content in the liver at seven days after 40mg/kg b.w. spherical shape MSN oral administration. This trend was in opposition with shot and long rod shape of MSN. However, there was no significant increase in hepatic enzyme markers or liver histological micro-morphology damage at 14 days after administration of MSN with various shape. Also, renal tubular impairment was found in that study (Li *et al.*, 2015). One previous study had been reported no toxicity after 90 days of oral administration of colloidal silica nanoparticles (20 and 100 nm size) given at 2000mg/kg dose (Kim *et al.*, 2014). Another study reporting hepatic toxicity with mononuclear infiltrate at the portal area and hepatocyte necrosis at the portal triads of the liver at 30 days after MSN (10mg/kg) IV administration (Xie *et al.*, 2010). To date, there was no report regarding the oral toxicity of cubical MSN used in this study. So further study is needed.

CONCLUSION

C-MSN used in this study showed excellent hepatoprotective properties with a significant decreasing number of necrotic cells compare with CCl₄ control group (2.6% lower; $p < 0.05$). C-MSN is a promising compound to be formulated as a

hepatoprotective agent. However, an oral toxicity study of MSN must be carried out first to determine its toxicity.

ACKNOWLEDGEMENT

We acknowledge the support from the Ministry of Research, Technology and Higher Education of Indonesia for providing a research grant under the national competition scheme (HIKOM 2017).

REFERENCES

- Abou Seif, HS., 2016. Physiological changes due to hepatotoxicity and the protective role of some medicinal plants. Beni-Suef Univ. J. Basic Appl. Sci. 5(2): 134–146. doi:10.1016/j.bjbas.2016.03.004
- Adaramoye, OA., Odunewu, AO., Farombi, EO., 2010. Hepatoprotective effect of Curcuma longa L. in D-galactosamine induced liver injury in mice: evidence of antioxidant activity. Afr. J. Med. Med. Sci. 39 Suppl 27–34.
- Amdalia, PR., Anwar, C., Kurnijasanti, R., 2017. Pengaruh Pemberian Ekstrak Daun Kelor (Moringa oleifera) terhadap Gambaran Histopatologi Sel Hepar Mencit Jantan yang Dipapar Metilmerkuri. J. Basic Med. Vet. 6(1): 1–7.
- Černý, D., Lekić, N., Váňová, K., Muchová, L., Hořánek, A., Kmoníčková, E., Zídek, Z., Kameníková, L., Farghali, H., 2011. Hepatoprotective effect of curcumin in lipopolysaccharide/-galactosamine model of liver injury in rats: Relationship to HO-1/CO antioxidant system. Fitoterapia. 82(5): 786–791. doi:10.1016/J.FITOTE.2011.04.003
- Farida, Y., Andayani, TM., Ratnasari, N., 2013. Analisis penggunaan obat pada komplikasi sirosis hati. J. Manaj. dan Pelayanan Farm. 4(2): 77–84.

- Farzaei, M., Zobeiri, M., Parvizi, F., El-Senduny, F., Marmouzi, I., Coy-Barrera, E., Naseri, R., Nabavi, S., Rahimi, R., Abdollahi, M., 2018. Curcumin in Liver Diseases: A Systematic Review of the Cellular Mechanisms of Oxidative Stress and Clinical Perspective. *Nutrients*. 10(7): 855. doi:10.3390/nu10070855
- Girish, C., Pradhan, SC., 2012. Hepatoprotective activities of picroliv, curcumin, and ellagic acid compared to silymarin on carbon-tetrachloride-induced liver toxicity in mice. *J. Pharmacol. Pharmacother.* 3(2): 149–55. doi:10.4103/0976-500X.95515
- Hartono, SB., Hadisoewignyo, L., Yang, Y., Meka, AK., Antaresti, Yu, C., 2016. Amine functionalized cubic mesoporous silica nanoparticles as an oral delivery system for curcumin bioavailability enhancement. *Nanotechnology*. 27(50): 505605. doi:10.1088/0957-4484/27/50/505605
- Hismiogullari, SE., Hismiogullari, AA., Sunay, FB., Paksoy, S., Can, M., Aksit, H., Karaca, O., 2014. The protective effect of curcumin on carbon tetrachloride induced liver damage. *Rev. Med. Vet. (Toulouse)*. 7–8(165): 194–200.
- Kim, Y., You, Y., Yoon, H., Lee, Y-H., Kim, K., Lee, J., Kim, MS., Kim, J., Jun, W., 2014. Hepatoprotective effects of fermented *Curcuma longa* L. on carbon tetrachloride-induced oxidative stress in rats. *Food Chem.* 151 148–153. doi:10.1016/j.foodchem.2013.11.058
- Kim, YR., Lee, SY., Lee, EJ., Park, SH., Seong, NW., Seo, HS., Shin, SS., Kim, SJ., Meang, EH., Park, MK., Kim, MS., Kim, CS., Kim, SK., Son, SW., Seo, YR., Kang, BH., Han, BS., An, SSA., Lee, BJ., Kim, MK., 2014. Toxicity of colloidal silica nanoparticles administered orally for 90 days in rats. *Int. J. Nanomedicine*. 9(December): 67–78. doi:10.2147/IJN.S57925
- Lee, G-H., Lee, H-Y., Choi, M-K., Chung, H-W., Kim, S-W., Chae, H-J., 2017. Protective effect of *Curcuma longa* L. extract on CCl₄-induced acute hepatic stress. *BMC Res. Notes*. 10(1): 77. doi:10.1186/s13104-017-2409-z
- Li, L., Liu, T., Fu, C., Tan, L., Meng, X., Liu, H., 2015. Biodistribution, excretion, and toxicity of mesoporous silica nanoparticles after oral administration depend on their shape. *Nanomedicine Nanotechnology, Biol. Med.* 11(8): 1915–1924. doi:10.1016/j.nano.2015.07.004
- Manfo, FPT., Nantia, EAN., Kuete, V., 2014. Toxicological Survey of African Medicinal Plants., in: Kuete, V. (Ed.), *Toxicological Survey of African Medicinal Plants*. Elsevier, London, pp. 323–355. doi:10.1016/C2013-0-15406-2
- Marslin, G., Prakash, J., Qi, S., Franklin, G., 2018. Oral delivery of curcumin polymeric nanoparticles ameliorates CCl₄-induced subacute hepatotoxicity in wistar rats. *Polymers (Basel)*. 10(5):. doi:10.3390/polym10050541
- Nayak, A., Raikar, A., Kotrashetti, V., Nayak, R., Shree, S., Kambali, S., 2016. Histochemical detection and comparison of apoptotic cells in the gingival epithelium using hematoxylin and eosin and methyl green-pyronin: A pilot study. *J. Indian Soc. Periodontol.* 20(3): 294–8. doi:10.4103/0972-124X.182601
- Omosa, LK., Midiwo, JO., Kuete, V., 2017. *Curcuma longa*, in: Kuete, Victor (Ed.), *Medicinal Spices and Vegetables From Africa*. Elsevier Inc., London, pp. 425–435.
- Paolo, P., Kateri, Y., 2017. TESIS Título : “ Efecto hepatoprotector del extracto acuoso liofilizado de *Curcuma longa* L. en daño hepático agudo inducido por tetracloruro de carbono en ratas albinas ”. TESIS : TÍTULO : “ Efecto hepatoprotector del extracto acuoso liofilizado de Curcu.
- Park, E., Jeon, CH., Ko, G., Kim, J., Sohn, DH., Al, EPET., 2000. Protective Effect of Curcumin in Rat Liver Injury Induced by Carbon Tetrachloride. 437–440.
- Reyes-Gordillo, K., Shah, R., Lakshman, MR., Flores-Beltrán, RE., Muriel, P., 2012. Hepatoprotective Properties of Curcumin., in: Muriel, Pablo (Ed.), *Liver Pathophysiology: Therapies and Antioxidants*. Elsevier Inc., London, pp. 687–704.
- Saygili, OK., Paksoy, S., Hismiogullari, SE., Kus, MA., Sunay, FB., Gulcen, B., Ozcan, E., 2016. Prevention of Carbon Tetrachloride-Induced Liver Injury in Rats by Omega-3 Fatty Acids. *Acta Medica Mediterr.* 33 137–144. doi:10.19193/0393-6384_2017_1_021
- Sengupta, M., Sharma, GD., Chakraborty, B., 2011. Hepatoprotective and immunomodulatory properties of aqueous extract of *Curcuma longa* in carbon tetra chloride intoxicated Swiss albino mice. *Asian Pac. J. Trop. Biomed.* 1(3): 193–199. doi:10.1016/S2221-1691(11)60026-9

- Singh, N., Khullar, N., Kakkar, V., Kaur, IP., 2014. Attenuation of carbon tetrachloride-induced hepatic injury with curcumin-loaded solid lipid nanoparticles. *BioDrugs*. 28(3): 297–312. doi:10.1007/s40259-014-0086-1
- Song, E-K., Cho, H., Kim, J-S., Kim, N-Y., An, N-H., Kim, J-A., Lee, S-H., Kim, Y-C., 2001. Diarylheptanoids with Free Radical Scavenging and Hepatoprotective Activity in vitro from *Curcuma longa*. *Planta Med*. 67(9): 876–877. doi:10.1055/s-2001-18860
- Tandi, J., 2017. Pola Penggunaan Obat Pada Pasien Penyakit Hati Yang Menjalani Rawat Inap Di Rumah Sakit Umum Daerah Undata Palu. *J. Pengemb. Sumber Daya Insa*. 02(02): 218–223.
- Virgonita, S., Karim, A., 2012. **Pola Penggunaan Obat pada Pasien Sirosis Hati di Instalasi Rawat Inap Bangsal Penyakit Dalam Rumah Sakit Dr. Sardjito Yogyakarta**. *Maj. Farm*. 8(3): 218–226.
- Wu, S-J., Lin, Y-H., Chu, C-C., Tsai, Y-H., Chao, JC-J., 2008. Curcumin or Saikosaponin a Improves Hepatic Antioxidant Capacity and Protects Against CCl₄ -Induced Liver Injury in Rats. *J. Med. Food*. 11(2): 224–229. doi:10.1089/jmf.2007.555
- Xie, G., Sun, J., Zhong, G., Shi, L., Zhan, D., 2010. Biodistribution and toxicity of intravenously administered silica nanoparticles in mice. *Arch. Toxicol*. 84(3): 183–190. doi:10.1007/s00204-009-0488-x
- Zhao, Y., Ma, X., Wang, J., He, X., Hu, Y., Zhang, P., Wang, R., Li, R., Gong, M., Luo, S., Xiao, X., 2014. Curcumin protects against ccl₄-induced liver fibrosis in rats by inhibiting HIF-1 α through an erk-dependent pathway. *Molecules*. 19(11): 18767–18780. doi:10.3390/molecules191118767

[IJP] Editor Decision

From: Editorial MFI (mfi@ugm.ac.id)

To: lanhadi@yahoo.com

Date: Friday, May 31, 2019 at 08:11 AM GMT+7

Dr Lannie Hadisoewignyo:

We have reached a decision regarding your submission to Indonesian Journal of Pharmacy, "Hepatoprotective effects of Curcumin-Mesoporous Silica Nanoparticles on CCl 4 -induced Hepatotoxicity Wistar rats".

We are pleased to confirm that your manuscript entitled Indonesian Journal of Pharmacy, "Hepatoprotective effects of Curcumin-Mesoporous Silica Nanoparticles on CCl 4 -induced Hepatotoxicity Wistar rats". has been accepted for publication in Indonesian journal of Pharmacy.

However, please make payment to BNI (Account holder: Mawardi Ihsan, Account No. 0140244118), SWIFT: BNINIDJAXXX before we could send you the official letter of acceptance.

Thank you very much for submitting your manuscript to the Indonesian Journal of Pharmacy

Sincerely,
Editorial MFI
Faculty of Pharmacy, Universitas Gadjah Mada
mfi@ugm.ac.id

INDONESIAN JOURNAL OF PHARMACY
Faculty of Pharmacy, Universitas Gadjah Mada
Skip Utara, 55281 Yogyakarta



LH.pdf
397kB