

# Vol 5, No 3 (2023)

## July

DOI: <https://doi.org/10.33508/jwmj.v5i3>

## Table of Contents

### ARTICLES

CRP LEVEL WITH THE SEVERITY OF COVID-19 PATIENTS AT GOTONG ROYONG HOSPITAL SURABAYA Christopher Christopher, Mulya Dinata, Yudita Wulandari	<a href="#">PDF</a> 127-131
SLEEP QUALITY AND COLLEGE STUDENT BLOOD PRESSURE IN WIDYA MANDALA CATHOLIC UNIVERSITY SURABAYA Cindy Clareta, Pauline Meryana, Endang Isbandiati	<a href="#">PDF</a> 132-137
THE DEGREE OF COLORECTAL CANCER DIFFERENTIATION AND INFILTRATION WITH TISSUE INTELEUKIN 6 EXPRESSION Stanley Sugihwardojo, Bernadette Dian Novita, Imelda Theodora	<a href="#">PDF</a> 138-145
THE EFFECT OF CIGARETTE SMOKE ON MUCOCILIARY TRANSPORT IN ALLERGIC RHINITIS PATIENTS AT PHC SURABAYA HOSPITAL Viola Gloria Legestino, Irene Lingkan Parengkuan, Irene Lingkan Parengkuan, Wiyono Hadi, Wiyono Hadi	<a href="#">PDF</a> 146-151
AGE AND GENDER WITH DEGREE OF HYPERTENSION IN ADULTS AT THE CARDIOLOGY CLINIC OF GOTONG ROYONG HOSPITAL IN SURABAYA Putu Raka Prema Aristian, Epriyanto Tri Darmadi, Maria Patricia Dian Putri	<a href="#">PDF</a> 152-155
THE EFFECT OF DRY RED JUJUBE FRUIT EXTRACT ON RATE ALKALINE PHOSPHATASE INDUCED WISTAR RATS ACETAMINOPHEN Maria Aloysia Praldinya Ere, Adi Pramono Hendrata, Laura Wihanto	<a href="#">PDF</a> 156-161
EFFECT OF ORAL INTAKE OF MICROPLASTIC ON THE CHANGES IN NEPHRON STRUCTURE AMONG MALE WISTAR RATS Priskilla Naomi Palyama, Yudhiakuari Sincihu, Irene Lingkan Parengkuan	<a href="#">PDF</a> 162-169
EFFECT OF MICROPLASTIC ORAL INTAKE ON FATTY DEGENERATION AND NECROSIS OF HEPATOCYTES IN WISTAR RATS Adinda Putri Studiyasari, Yudhiakuari Sincihu, Irene Lingkan Parengkuan, Bernadette Dian	<a href="#">PDF</a> 170-177

ACCREDITED



Authors Guidelines

Article Template

### ABOUT THE JOURNAL

Online Submissions

Editorial Team

Reviewer

Focus and Scope

Open Access Policy

Publication Ethics and Malpractice Statement

Peer Review Process

Copyright Notice

Plagiarism Check

Article Processing Charge

Announcements

Contact Us

### REFERENCE TOOLS

Every article submitted to **Journal of Widya Medika Junior** shall use reference management software e.g. **Mendeley**.



use **Vancouver citation style**, download [here](#)

### User

Username

Password

Remember me

[Login](#)



## EFFECT OF MICROPLASTIC ORAL INTAKE ON FATTY DEGENERATION AND NECROSIS OF HEPATOCYTES IN WISTAR RATS

*Adinda Putri Studyasari, Yudhiakuari Sincihu, Irene Lingkan Parengkuan, Bernadette Dian Novita*

### Abstract

**Introduction:** In the human body, microplastics are considered toxic agents. Low-density polyethylene (LDPE) has very high chemical resistance, making it very difficult to be degraded by microorganisms. LDPE plastic would be degraded to a smaller size and could not be completely degraded by microorganisms. Plastic packaging made from LDPE is the most commonly found plastic waste. Microplastics may cause cell injury, especially cells in the liver, the primary organ for detoxification. Microplastic induces reactive oxygen species, which leads to oxidative stress. Prolonged exposure to microplastics leads cells unable to cope with the toxic effects. Furthermore, this process triggers fatty degeneration and necrosis. This study aims to explain the correlation between microplastic oral intake with fatty degeneration and necrosis of hepatocytes in animal models. **Methods:** Forty-two Wistar rats were involved and assigned to one control and five experimental groups. The experimental groups were given microplastic exposure starting from 0.0375 mg/day to 0.6 mg daily for 90 days. **Results:** Fatty degeneration and necrosis were observed using a light microscope with hematoxylin-eosin staining. There was a significant correlation between microplastic oral intake and hepatocyte necrosis ( $p < 0.05$ ). The higher the exposure dose, the more hepatocyte necrosis. In contrast, there was no correlation between microplastic exposure and fatty degeneration. Ingestion of microplastics leads to hepatocyte necrosis. **Conclusion:** Oral intake of LDPE microplastics with  $< 20 \mu\text{m}$  in size for 90 days in Wistar rats leads to hepatocellular injury. Based on histopathological images, hepatocyte necrosis was more prominent than hepatocyte fatty degeneration.

### Save to Mendeley



### Keywords

Fatty degeneration; Hepatocyte; Low-density polyethylene; Microplastics

### Full Text:

[PDF](#)

### References

ACCREDITED



[Authors Guidelines](#)

[Article Template](#)

#### ABOUT THE JOURNAL

[OnLine Submissions](#)

[Editorial Team](#)

[Reviewer](#)

[Focus and Scope](#)

[Open Access Policy](#)

[Publication Ethics and Malpractice Statement](#)

[Peer Review Process](#)

[Copyright Notice](#)

[Plagiarism Check](#)

[Article Processing Charge](#)

[Announcements](#)

[Contact Us](#)

#### REFERENCE TOOLS

Every article submitted to **Journal of Widya Medika Junior** shall use reference management software e.g. **Mendeley**.



use **Vancouver citation style**,  
[download here](#)

## EFFECT OF MICROPLASTIC ORAL INTAKE ON FATTY DEGENERATION AND NECROSIS OF HEPATOCYTES IN WISTAR RATS

Adinda Putri Studytasari<sup>1)</sup>, Yudhiakuari Sincihu<sup>1)</sup>, Irene Lingkan Parengkuan<sup>2)</sup>,  
Bernadette Dian Novita<sup>3)</sup>

Corresponding email: [adindaps12@gmail.com](mailto:adindaps12@gmail.com)

<https://doi.org/10.33508/jwmj.v5i3.4832>

### ABSTRACT

**Introduction:** In the human body, microplastics are considered toxic agents. Low-density polyethylene (LDPE) has very high chemical resistance, making it very difficult to be degraded by microorganisms. LDPE plastic would be degraded to a smaller size and could not be completely degraded by microorganisms. Plastic packaging made from LDPE is the most commonly found plastic waste. Microplastics may cause cell injury, especially cells in the liver, the primary organ for detoxification.

**Purpose:** This study aims to explain the correlation between microplastic oral intake with fatty degeneration and necrosis of hepatocytes in animal models.

**Methods:** Forty-two Wistar rats were involved and assigned to one control and five experimental groups. The experimental groups were given microplastic exposure starting from 0.0375 mg/day to 0.6 mg daily for 90 days.

**Results:** Fatty degeneration and necrosis were observed using a light microscope with hematoxylin-eosin staining. There was a significant correlation between microplastic oral intake and hepatocyte necrosis ( $p < 0.05$ ). The higher the exposure dose, the more hepatocyte necrosis. In contrast, there was no correlation between microplastic exposure and fatty degeneration. Ingestion of microplastics leads to hepatocyte necrosis.

**Conclusion:** Oral intake of LDPE microplastics with  $< 20 \mu\text{m}$  in size for 90 days in Wistar rats leads to hepatocellular injury. Based on histopathological images, hepatocyte necrosis was more prominent than hepatocyte fatty degeneration.

**Keywords:** Fatty degeneration, Hepatocyte, Low-density polyethylene, Microplastics, Necrosis

### Abbreviation :

LDPE = Low-Density Polyethylene

ROS = Reactive Oxygen Species

DNA = Deoxyribonucleic acid

<sup>1)</sup> Faculty of Medicine, Widya Mandala Surabaya Catholic University Email: [adindaps12@gmail.com](mailto:adindaps12@gmail.com)

<sup>2)</sup> Department of Pathology anatomy, Faculty of Medicine, Widya Mandala Surabaya Catholic University

<sup>3)</sup> Department of Pharmacology,, Faculty of Medicine, Widya Mandala Surabaya Catholic University

## INTRODUCTION

Plastic waste has become a global issue due to its use in large quantities, leading to an increase in world plastic production. Plastic packaging is made from Low-Density Polyethylene (LDPE) plastic. LDPE is known for its flexibility and shape ability. However, this type of plastic is the most difficult material to decompose. Microplastics derived from low-density polyethylene are society's most common type of plastic.(1)

Microplastic is generally a small piece of plastic of less than 5 mm. Such a definition has been generally used since microplastics are considered to have a certain small size, consumed by many aquatic biota species.(2) There are 2 types of microplastics: primary and secondary. Primary microplastics are plastics produced in small sizes for a specific purpose, for example, in cosmetic products such as facial scrubs and toothpaste. Secondary microplastics are microplastics that come from plastic products that are disintegrated by ultraviolet light.(3) Given the large amount of plastic production and use, it could be assumed that most of the microplastics in the environment are secondary microplastics.(4)

Low-density polyethylene has very high chemical resistance, making it very difficult to be degraded by microorganisms. Low-density polyethylene plastic would be degraded to a smaller size and could not be completely degraded by microorganisms. Data regarding plastic waste from 2016 to 2019 revealed that plastic packaging made from low-density polyethylene is the most common plastic waste.(1) Therefore, the current study used low-density polyethylene plastic, mostly found in the household environment due to its use in daily life. Microplastics are considered strange and toxic agents by the body, which may cause injury to body cells, especially hepatocytes in

the liver, as the primary organ for detoxification in the body's defense system. When cells are still able to cope with strange objects that enter the body, cause cells to reversible damage and then return to normal condition, such as fatty degeneration. Fatty degeneration is a condition wherein cells experience intracytoplasmic accumulation of triglycerides. Severe or prolonged stress makes cells unable to cope with the effects of foreign bodies. It causes experience irreversible damage or be unable to return to their original state, called necrosis.

A study by Zheng et al. revealed that the isolation of hepatocytes in 3-month-old rats exposed to 50 nm polystyrene microplastics for 24 hours could induce Reactive Oxygen Species (ROS) and cause DNA damage. This study aims to explain the correlation between microplastic oral intake with fatty degeneration and necrosis of hepatocytes in the Wistar rat liver.

## MATERIAL AND METHODS

### Research Design

This was an experimental study with a post-test-only control group design to determine the effect of microplastics on fatty degeneration and necrosis of hepatocytes among Wistar rats. The samples were 42 male Wistar rats aged 2-3 months with a body weight of  $150 \pm 20$  grams, which were assigned into 6 groups through random allocation. The Lemeshow formula determined the sample size with  $\alpha=0.05$  and  $\beta=0.03$ , which resulted in seven rats for each group. The control group (C) was not exposed to microplastics. In contrast, the experimental groups were exposed to microplastics in certain microplastic doses of 0.0375 to 0.6 mg daily for experimental groups six different experimental groups, respectively. These groups were given dry powdered microplastics mixed with one cc of distilled water per os for 90 days.

## Experimental Animal

Wistar rats were purchased from the Farma Veterinary Center in Surabaya, along with a certificate of proper animal ethics for trials. The Wistar rats were housed in groups of two rats per ventilated cages with a 12/12 hour light/dark cycle and provided with enough food and water. The temperature was maintained at 18-20°C (291-293°K), and humidity was maintained at 40-70%. Initially, the rats were weighed. The animal's body weight was 150±20grams (2-3 months old)

## Exposure Material

Low-Density Polyethylene Microplastics were obtained from plastic food packaging (Fig. 1A), which was processed using Fomac-FCT Z100 many times to get the appropriate size of <20 µm (according to a previous study by Deng et al., 2017). The microplastic powder was then filtered using an 800mesh sieve (Fig. 1B). In the next stage, microplastics were observed under a microscope using the Nikon Eclipse Binocular Microscope Ci-L-DS-F12-L3, with a magnification of 400 with a scale of 10 µm (Fig. 1C). The exposure material in this study appeared to have irregular shapes of <20 µm. Sharp-edged microplastics appeared solid in opaque under a microscope.

**Fig. 1.** Exposure material



**Fig. 1.** Exposure material

## Examination of Hepatocyte Histopathology

Preservation and sampling of the Wistar rat's livers were carried out at the Animal Laboratory of the Widya Mandala Catholic University of Surabaya. Livers were sent to Airlangga University in Surabaya for paraffin preparations. Furthermore, histopathological slides stained with

hematoxylin-eosin were prepared by Jombang's Regional General Hospital. Examination of the microscopic structure of the liver aims to observe normal hepatocytes, necrosis, and fatty degeneration were done with 400x magnification of light microscope in ten fields of view by two pathologists at Airlangga University.

## Statistical Analysis

Correlation analysis to determine variables were performed using Spearman's rho.

## Ethical Statement

This study was conducted according to the Helsinki ethical procedures and obtained an ethical certificate from the Health Research Ethics Committee of the Widya Mandala Catholic University of Surabaya (Reference number 0244/WM12/KEPK/MHS/T/2022).

## RESULTS

### Number of Fatty Degeneration and Necrosis of Hepatocytes

The variables of fatty degeneration and necrosis of hepatocytes were not normally distributed (p-value of >0.05) through the Shapiro-Wilk test. The results of the correlation analysis were considered significant if a p-value of <0.05 was obtained with a 95% confidence interval.

In Fig. 2A, the mean number of fatty degeneration in the control group was 4.4±2.1; 34.7±62.2 for the group X1; 15.3±8.6 for the group X2; 15±15.7 for group X3; 7.7±5.2 for the group X4; and 7.1±3.6 for the group X5. The group X1 given the lowest exposure dose appeared to have the highest number of hepatocyte fatty degeneration. It was shown to have the mildest toxic effect among the other groups. The number of fatty degeneration decreased as the exposure dose increased. In Fig. 2B, there was an increase in the amount of hepatocyte necrosis and the increasing dose of microplastic exposure. The mean number of necrosis in the control group was 18.2±5.7; 5.8±7.4 for the group

Variable	Statistical test	p-value	r value
Fatty degeneration	Spearman's rho	0.122	-
Necrosis	Spearman's rho	0.001	+0.853

X1; 26.8±9 for the group X2; 36.6±7.1 for group X3; 54.9±7.8 for group X4; 58.1±8.6 for the group X5. Based on Fig. 2, it could be seen that the number of fatty degeneration of hepatocytes decreased since hepatocytes could not compensate for high doses of microplastics and experienced necrosis. The mean number of necrosis in the control group was 115.6±31.2; 109.4±43.3 for the group X1; 102.7±18.4 for the group X2; 96.9±5.8 for group X3; 88.5±19.9 for the group X4; 71±14.3 for the group X5. Based on Fig. 2C, it could be seen that the number of normal hepatocytes decreased since hepatocytes could not be able to cope with the toxicity of microplastic exposure.

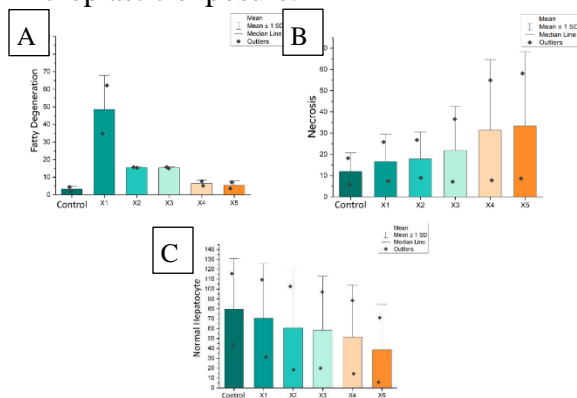


Fig. 2. A). Mean number of fatty degeneration, B). Mean number of necrosis C). Mean number of normal hepatocytes

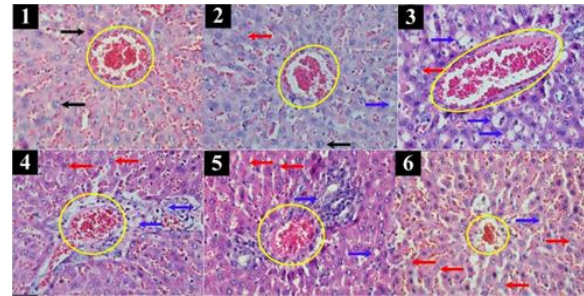


Fig. 3. Microscopic view of fatty degeneration and necrosis of hepatocytes with Hematoxylin Eosin staining, 400x magnification. Description: Yellow circle: hepatic portal vein; black arrow: normal hepatocytes; blue arrow: fatty degeneration; red arrow: necrosis.

### Correlation Analysis

The statistical analysis results between microplastic doses and hepatocyte necrosis obtained a p-value of 0.000 ( $p < 0.05$ ), indicating a correlation between both variables. The r value was 0.853 ( $r > 0.8$ ) with a positive or unidirectional correlation. This indicated that the higher the dose of microplastic, the greater the number of hepatocyte necrosis. Meanwhile, the correlation test results between microplastic doses and fatty degeneration obtained a p-value of 0.122 ( $p < 0.05$ ), indicating no correlation between both variables.

Table I. Correlation analysis between microplastic doses with fatty degeneration and necrosis

### DISCUSSION

Low-Density Polyethylene (LDPE), as a global environmental issue, has shown its toxicity effect by causing oxidative stress in the liver. Low-density polyethylene is used as the main ingredient for food and beverage packaging. LDPE is known for its flexibility and shape ability. However, this type of plastic is the most difficult plastic material to decompose. Microplastics derived from low-density

polyethylene are the most common type of plastic found in daily life. Plastic food and beverage packaging is the most common waste found in the environment; food and beverage packaging contributes almost 50% of the global plastic total weight.(5) Due to its widespread use, low-density polyethylene was chosen as the variable in this study. Microplastics made from low-density polyethylene contain several materials, such as carbon polymers with oxygen, chlorine, nitrogen, and sulfur. These materials could induce oxidative stress due to free radical exposure.

Microplastics in the body absorb in the gastrointestinal tract and enter the circulation, then distribute to target organs.(6) The absorption of microplastics in the lumen of the digestive tract occurs through paracellular perception, which is a mechanical process in solid particles. These particles can pass through the gaps in the single-layer epithelium found at the end of the digestive tract villi, which enter the blood circulation system with dendritic cells and are then distributed to secondary tissues, such as the liver.(7) Blood that has carried microplastics from the mesenteric vein in the intestinal segment then returns to the liver via the hepatic portal vein. Microplastics in the body are considered foreign bodies and have toxic effects. This may cause injury to the body cells, especially hepatocyte cells in the liver, the primary organ for detoxification of the body's defense system. The liver is the frontline immune organ to detect and clear foreign pathogens in the blood. Liver cells are the part of the liver that carries out almost all of the liver's detox functions.(8) Microplastics have a hepatotoxic effect associated with increased ROS levels. Such increase further causes oxidative stress and affects cells, causing damage to all cell components, even cell death or necrosis.(9) The high level of ROS in the body affects

the hepatocyte necrosis process. Oxidative stress in the liver leads to liver disorders, especially fat and energy metabolism.(10)

Based on the study findings, microplastic oral intake had a significant effect for 90 days on hepatocyte necrosis, as presented in the microscopic image of hepatocyte necrosis of the *Rattus norvegicus* Wistar strain. Long-term exposure to toxic agents such as microplastics causes an injury to hepatocytes. Hepatocytes experience fatty degeneration and try to adapt to the toxicity of microplastic ingredients. If this exposure continues beyond the adaptability of hepatocytes, hepatocytes experience necrosis or permanent cell death. Necrosis is a type of permanent cell death with membrane integrity loss and cell contents leakage resulting in cell damage. Necrosis is irreversible cell damage, and the cells cannot return to their normal function.(11)

A previous study showed that microplastics with a size of  $\leq 20\mu\text{m}$  could accumulate and cause inflammation and necrosis in rat livers at a dose of 0.5 mg/day for 28 days of exposure.(12) The other previous study, which used 0-2000  $\mu\text{m}$ -sized microplastics, showed severe liver damage.(13) This study showed a significant correlation between microplastic oral intake and hepatocyte necrosis. The higher microplastic oral intake was associated with an increase in hepatocyte necrosis but not fatty degeneration. Such a finding aligns with the previous study on the toxicity effect of microplastic on the liver.

ROS concentration and liver function also need to be measured; however, in this study, that markers were not included due to ROS's lifespans. Most types of ROS are short-lived, it lifespans of milliseconds or less. ROS has low steady-state levels and changes rapidly. ROS affected by continuously varying rates of

generation, diffusion, and chemical reaction.(14)

However, there was no correlation between oral intake of microplastic for 90 days with fatty degeneration based on the microscopic image of liver cells of *Rattus norvegicus* Wistar

strain. A previous study conducted by Deng et al. in 2017 revealed that administering microplastic to rats could trigger the fatty degeneration of hepatocyte cells. It was found that exposure to microplastics in rats for four weeks could cause changes in hepatocytes. (12) Furthermore, a previous study conducted by Li L et al. in 2021 found that exposure to microplastics for 15 days could cause fatty degeneration of rat hepatocytes.(15) In this study, rats were exposed to microplastics orally for 90 days. The insignificant correlation between the administration of oral microplastics and fatty degeneration of hepatocyte cells was due to the study period. The administration of microplastic for 90 days caused hepatocytes' failure to adapt; this is the reason why fatty degeneration is rarely found. Although the data analysis did not show a correlation between the administration of microplastic doses and fatty degeneration of hepatocyte cells, it could be seen a decrease in fatty degeneration levels in groups X1 to X5. Thus, the more doses of microplastics given, the more toxic effects on the cells caused cell necrosis.

This study shows that the more doses of microplastics given, the more toxic effects on the hepatocyte cells in the liver. This toxic effect could cause necrosis or permanent cell death. This effect could be dangerous to human health. Exposure to microplastics could be minimized by reducing plastic use, especially plastic packaging, which has the most plastic waste in the environment. Proper

processing of plastic waste would help reduce microplastic exposure to aquatic organisms. Humans are exposed to microplastics through several pathways, such as ingestion, inhalation, and dermal contact. Ingestion is the easiest pathway microplastics enter the human body. Microplastics could easily enter the food chain by trophic transfer through seafood.(16) Crops watered with contaminated water are also another pathway of human exposure to microplastics through ingestion. Contaminated water is used to grow the crops, and then plastics being degraded continuously in the soils where the crops are cultivated. (17,18,19,20)

## CONCLUSIONS

Oral intake of low-density polyethylene secondary microplastics with <20 µm in size for 90 days in white Wistar rats lead to hepatocellular injury. Based on histopathological images, hepatocyte

necrosis was more prominent than hepatocyte fatty degeneration. The fifth group with the highest microplastics dose showed the highest amount of necrosis than the other groups. Meanwhile, the first group with the lowest microplastic dose showed the highest amount of fatty degeneration than the other groups.

## ACKNOWLEDGEMENTS

We would like to express sincere gratitude to all staff of the Animal and Research Laboratory of the Faculty of Pharmacy, Widya Mandala Catholic University of Surabaya, the Anatomical Pathology Laboratory of Airlangga University, Surabaya, and the Jombang's Regional General Hospital for their participation in this study.



**REFERENCES**

1. Green Peace. Throwing Away the Future: Throwing Away The Future: How Companies Still Have It Wrong on Plastic Pollution “Solutions”. Green Peace. 2019.
2. Lusher A, Hollman PCH, Mendoza-Hill J, Food and Agriculture Organization of the United Nations. Microplastics in fisheries and aquaculture: status of knowledge on their occurrence and implications for aquatic organisms and food safety. 126 p.
3. Sarmah R, Bhagabati S, Dutta R, Baishya S, Choudhury A, Bhagabati SK, et al. Microplastic pollution: An emerging environmental issue National Surveillance Programme for Aquatic Animal Diseases View project ICAR-NAIP (Component III) View project Microplastic pollution: An emerging environmental issue. *J Entomol Zool Stud* [Internet]. 2018;6(6). Available from: <https://www.researchgate.net/publication/328955573>
4. Efimova I, Bagaeva M, Bagaev A, Kileso A, Chubarenko IP. Secondary microplastics generation in the sea swash zone with coarse bottom sediments: Laboratory experiments. *Front Mar Sci*. 2018 Sep 5;5(SEP).
5. Ncube LK, Ude AU, Ogunmuyiwa EN, Zulkifli R, Beas IN. An overview of plastic waste generation and management in food packaging industries. *Recycling*. 2021 Mar 1;6(1):1–25.
6. Revel M, Châtel A, Mouneyrac C. Micro(nano)plastics: A threat to human health? Vol. 1, *Current Opinion in Environmental Science and Health*. Elsevier B.V.; 2018. p. 17–23.
7. Wright SL, Kelly FJ. Plastic and human health: a micro issue? [Internet]. *Environ. Sci. Technol.*, Just Accepted Manuscript • Publication Date. 2017. Available from: <http://pubs.acs.org>
8. Kalra A, Yetiskul E, Wehrle CJ, Tuma F. Physiology, Liver. *StatPearls* [Internet]. 2022 May 8;
9. Noreen A, Bukhari DA, Rehman A. Reactive oxygen species: Synthesis and their relationship with cancer-A review. Vol. 50, *Pakistan Journal of Zoology*. University of Punjab (new Campus); 2018. p. 1951–63.
10. Chang X, Xue Y, Li J, Zou L, Tang M. Potential health impact of environmental micro-and nanoplastics pollution. Vol. 40, *Journal of Applied Toxicology*. John Wiley and Sons Ltd; 2020. p. 4–15.
11. Kubes P, Jenne C. Immune Responses in the Liver. *Annu Rev Immunol* [Internet]. 2018;36(1):247–77. Available from: <https://doi.org/10.1146/annurev-immunol-051116-052415>
12. Deng Y, Zhang Y, Lemos B, Ren H. Tissue accumulation of microplastics in mice and biomarker responses suggest widespread health risks of exposure. *Sci Rep*. 2017;7.
13. Hu J, Zuo J, Li J, Zhang Y, Ai X, Zhang J, et al. Effects of secondary polyethylene microplastic exposure on crucian (*Carassius carassius*) growth, liver damage, and gut microbiome composition. *Science of the Total Environment*. 2022 Jan 1;802.
14. Murphy MP, Bayir H, Belousov V, Chang CJ, Davies KJA, Davies MJ, et al. Guidelines for measuring reactive oxygen species and oxidative damage in cells and in vivo. *Nat Metab*. 2022 Jun 1;4(6):651–62.

17. Li L, Xu M, He C, Wang H, Hu Q. Polystyrene nanoplastics potentiate the development of hepatic fibrosis in high-fat diet fed mice. *Environ Toxicol.* 2022 Feb 1;37(2):362–72.
18. Domenech J, Marcos R. Pathways of human exposure to microplastics, and estimation of the total burden. Vol. 39, *Current Opinion in Food Science.* Elsevier Ltd; 2021. p. 144–51.
19. Ru W, Hu S, Ning J, Wang J, Gu Q, Guo Y, et al. Study on the Rheological Failure Mechanism of Weakly Cemented Soft Rock Roadway during the Mining of Close-Distance Coal Seams: A Case Study. *Advances in Civil Engineering.* 2020;2020.
20. Corradini F, Meza P, Eguiluz R, Casado F, Huerta-Lwanga E, Geissen V. Evidence of microplastic accumulation in agricultural soils from sewage sludge disposal. *Science of the Total Environment.* 2019 Jun 25;671:411–20.
21. Jaya DK, Sincihu Y, Suwasanti N. The effect of peroral polyvinyl chloride microplastic on the value of prothrombin time and activated partial thromboplastin time in *Rattus norvegicus* Wistar strain. *Widya Med Jr J.* 2022;4(3):163–70.
22. Wicaksono LS, Sincihu Y, Hendrata AP. The effect of peroral polyvinyl chloride microplastic on alkaline phosphatase and gamma-glutamyl transferase levels in *Rattus norvegicus* Wistar strain Leonardo. *Widya Med Jr J.* 2022;4(3):171–80.